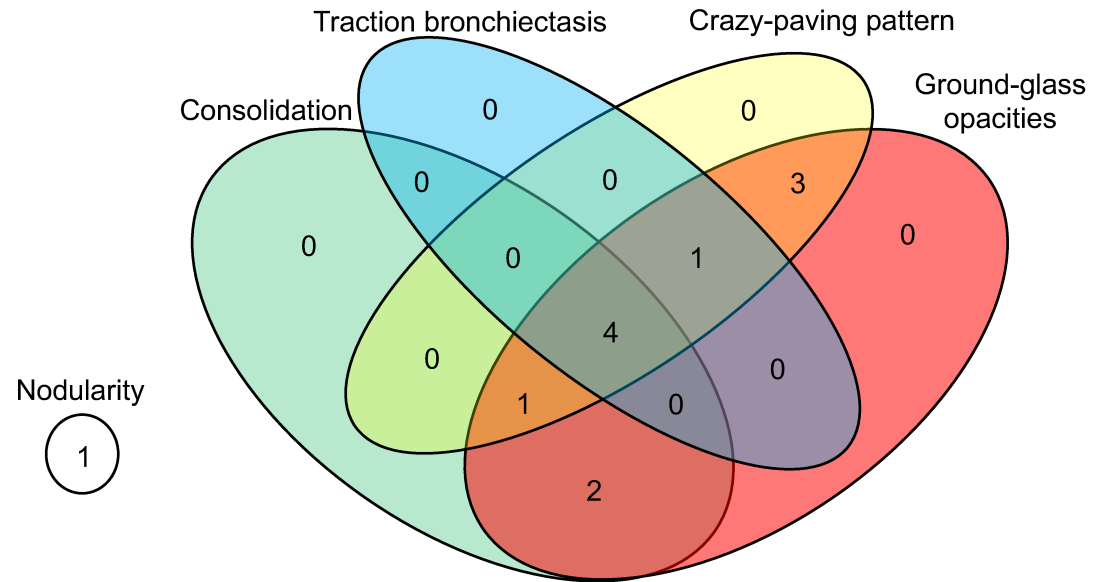


Supplemental Figure 1: Depiction of Infiltrate Type and Laterality of ICI-Pneumonitis upon Diagnostic Chest CT Scan



| Treatment group | IVIG | Infliximab | Combination |
|--|------|------------|-------------|
| CIP radiological characteristics | | | |
| Consolidation | | | |
| with GGOs | 1 | 0 | 1 |
| with GGOs + crazy-paving pattern | 0 | 1 | 0 |
| with GGOs + traction bronchiectasis + crazy-paving pattern | 4 | 0 | 0 |
| GGOs | | | |
| with crazy-paving pattern | 1 | 1 | 1 |
| with crazy-paving pattern + traction bronchiectasis | 0 | 0 | 1 |
| Nodularity alone | 1 | 0 | 0 |
| Laterality | | | |
| Unilateral | 2 | 1 | 0 |
| Bilateral | 5 | 1 | 3 |